



Hepatic phaeohyphomycosis due to a novel dematiaceous fungus, *Pleurostoma hongkongense* sp. nov., and importance of antifungal susceptibility testing

Chi-Ching Tsang , Ka-Fai Chan , Walton Chan , Jasper F. W. Chan , Rex K. H. Au-Yeung , Antonio H. Y. Ngan , Ken P. K. Lin , Susanna K. P. Lau & Patrick C. Y. Woo

To cite this article: Chi-Ching Tsang , Ka-Fai Chan , Walton Chan , Jasper F. W. Chan , Rex K. H. Au-Yeung , Antonio H. Y. Ngan , Ken P. K. Lin , Susanna K. P. Lau & Patrick C. Y. Woo (2021) Hepatic phaeohyphomycosis due to a novel dematiaceous fungus, *Pleurostoma hongkongense* sp. nov., and importance of antifungal susceptibility testing, *Emerging Microbes & Infections*, 10:1, 81-96, DOI: [10.1080/22221751.2020.1866955](https://doi.org/10.1080/22221751.2020.1866955)

To link to this article: <https://doi.org/10.1080/22221751.2020.1866955>



© 2021 The Author(s). Published by Informa UK Limited, trading as Taylor & Francis Group, on behalf of Shanghai Shangyixun Cultural Communication Co., Ltd



[View supplementary material](#)



Published online: 17 Jan 2021.



[Submit your article to this journal](#)



Article views: 781



[View related articles](#)



[View Crossmark data](#)

Hepatic phaeohyphomycosis due to a novel dematiaceous fungus, *Pleurostoma hongkongense* sp. nov., and importance of antifungal susceptibility testing

Chi-Ching Tsang ^{a*}, Ka-Fai Chan ^{a*}, Walton Chan ^a, Jasper F. W. Chan ^a, Rex K. H. Au-Yeung ^b, Antonio H. Y. Ngan^a, Ken P. K. Lin ^a, Susanna K. P. Lau ^a and Patrick C. Y. Woo ^a

^aDepartment of Microbiology, Li Ka Shing Faculty of Medicine, The University of Hong Kong, Pokfulam, Hong Kong; ^bDepartment of Pathology, Li Ka Shing Faculty of Medicine, The University of Hong Kong, Pokfulam, Hong Kong

ABSTRACT

Pleurostoma species are wood-inhabiting fungi and emerging opportunistic pathogens causing phaeohyphomycosis. In this study, we isolated a dematiaceous fungus, HKU44^T, from the subhepatic abscess pus and drain fluids of a liver transplant recipient with post-transplant biliary and hepatico-jejunostomy bypass strictures. Histology of the abscess wall biopsy showed abundant fungal hyphae. The patient survived after a second liver transplant and antifungal therapy. On SDA, HKU44^T grew initially as white powdery colonies which turned beige upon maturation. Hyphae were septate and hyaline. Phialides were monophialidic and laterally located, generally closely associated to a cluster of conidia which were usually reniform. Phylogenetic analyses showed that HKU44^T is most closely related to, but distinct from, *Pleurostoma ootheca* and *Pleurostoma repens*. These suggested that HKU44^T is a novel *Pleurostoma* species, for which the name *Pleurostoma hongkongense* sp. nov. is proposed. Antifungal susceptibility testing showed that *Pleurostoma* species possessed high MICs/MECs for fluconazole, 5-flucytosine and the echinocandins; whereas they exhibited a high strain-to-strain variability to the susceptibilities to the other triazoles. As for amphotericin B, ~65% of the *Pleurostoma* strains had low MICs (≤ 1 µg/mL). DNA sequencing should be performed to accurately identify fungi with *Pleurostoma*/*Phialophora*-like morphologies, so is antifungal susceptibility testing for patients with *Pleurostoma* infections.

ARTICLE HISTORY Received 18 June 2020; Revised 23 November 2020; Accepted 16 December 2020





KEYWORDS Liver; phaeohyphomycosis; dematiaceous fungus; *Pleurostoma*; *Pleurostoma hongkongense*; novel species

Introduction


Pleurostoma species are emerging human pathogens causing phaeohyphomycosis. This historic genus was originally established in 1863 [1]. Following its merging with the asexual genus *Pleurostomophora* subsequent to the abolishment of dual nomenclature of the different morphs of the same fungus since 2013, it currently accommodates a total of five species, namely *Pleurostoma candollei* (type species), *Pleurostoma ootheca*, *Pleurostoma ochraceum*, *Pleurostoma repens* and *Pleurostoma richardsiae* [2, 3]. In nature, this group of fungi inhabits woods [4, 5]; and they have also been isolated from soil and sewage [4] and found as contaminants which cause blueing of ground wood pulp [6]. Infection may result from close contact with *Pleurostoma*-contaminated plants or direct inoculation of contaminated materials into the body [7–11]. Very often *Pleurostoma* infections are localized and manifest as cutaneous or subcutaneous lesions and/or nodules [7–9, 11–30],

although infections of the bones/joints [9, 20, 22, 31–35], eyes [10, 35–37] and urinary tracts [38] are also observed. In more rare occasions especially in severely immunocompromised individuals, disseminated invasive infections affecting the bloodstreams, hearts and livers could also occur [35, 39, 40]. The aetiological agent for most of the cases were *Pleurostoma richardsiae* [7–25, 28–33, 35–40], while *Pleurostoma ochraceum* [26], *Pleurostoma ootheca* [27] and *Pleurostoma repens* [34] were also reported to cause infections in a few cases.

In 2017, we isolated a dematiaceous fungus from the subhepatic abscess pus and drain fluids of a patient. Microscopic examination of the fungal culture and preliminary internal transcribed spacer (ITS) region sequencing showed that it is a *Pleurostoma* species, although matrix-assisted laser desorption/ionization–time-of-flight mass spectrometry (MALDI–TOF MS) failed to identify this fungus due to the

CONTACT Patrick C. Y. Woo  pcywoo@hku.hk  Department of Microbiology, Li Ka Shing Faculty of Medicine, The University of Hong Kong, 19/F, Block T, Queen Mary Hospital Compound, Pokfulam, Hong Kong; Susanna K. P. Lau  skplau@hku.hk  Department of Microbiology, Li Ka Shing Faculty of Medicine, The University of Hong Kong, 19/F, Block T, Queen Mary Hospital Compound, Pokfulam, Hong Kong

*These authors contributed equally to this study.

 Supplemental data for this article can be accessed at <https://doi.org/10.1080/22221751.2020.1866955>.

© 2021 The Author(s). Published by Informa UK Limited, trading as Taylor & Francis Group, on behalf of Shanghai Shangyixun Cultural Communication Co., Ltd
This is an Open Access article distributed under the terms of the Creative Commons Attribution-NonCommercial License (<http://creativecommons.org/licenses/by-nc/4.0/>), which permits unrestricted non-commercial use, distribution, and reproduction in any medium, provided the original work is properly cited.

absence of interpretable protein mass spectra. Further morphological and molecular characterizations showed that this fungus is closely related to, but distinct from, all the known *Pleurostoma* species. Therefore, we propose a new species, *Pleurostoma hongkongense* sp. nov., to describe this fungus. Antifungal susceptibilities of this novel species and the known *Pleurostoma* species were also performed to help guide patient management.

Materials and methods

Patient and strains

Clinical specimens, including pus from a subhepatic abscess as well as drain fluids, were collected from the patient, handled according to standard protocols, directly inoculated on Sabouraud dextrose agars (SDA; Difco, BD Diagnostics Systems, USA) supplemented with chloramphenicol (50 µg/mL; Calbiochem, USA) and incubated at 30°C to obtain the case isolate HKU44^T. Fungal materials were harvested directly from a single colony for subsequent subcultures. Clinical data were collected by retrieving and analysing the hospital record of the patient, and the use of these data was approved by the Institutional Review Board of The University of Hong Kong/Hospital Authority Hong Kong West Cluster. The ex-type strains of *Pleurostoma ochraceum*, *Pleurostoma repens* and *Pleurostoma richardsiae*, a reference strain of *Pleurostoma ootheca* as well as 23 reference strains of *Pleurostoma richardsiae* originating from clinical sources were obtained from the American Type Culture Collection (ATCC), USA; the Medical Mycology Research Center (MMRC) of Chiba University (IFM), Japan; the National Collection of Pathogenic Fungi (NCPF), Public Health England (PHE), UK; the UAMH Centre for Global Microfungal Biodiversity, Dalla Lana School of Public Health, University of Toronto, Canada as well as the Westerdijk Fungal Biodiversity Institute (CBS), the Netherlands (Table S1). The quality control strains for susceptibility testing *Aspergillus flavus* ATCC 204304, *Aspergillus fumigatus* ATCC 204305 and *Candida parapsilosis* ATCC 22019^T were obtained from ATCC; *Candida albicans* CNM-CL F8555, *Pichia kudriavzevii* (synonym: *Candida krusei*) CNM-CL-3403 and *Aspergillus flavus* CNM-CM-1813 were obtained from Statens Serum Institut (SSI), Denmark; and *Pichia kudriavzevii* NRRL Y-413 (=ATCC 6258) was obtained from the Agricultural Research Service (ARS) Culture Collection (NRRL), Department of Agriculture, USA.

Phenotypic characterizations

The fungal isolate HKU44^T and other *Pleurostoma* ex-type/reference strains were cultured on malt extract agar (MEA; Oxoid, UK), potato dextrose agar (PDA;

BD Diagnostic Systems) and SDA (all supplemented with chloramphenicol [50 µg/mL]) for examination of growth rates and colony characteristics. Images of the fungal colonies were captured using the digital camera α5100 (Sony, Japan). For light microscopy, a slide culture was prepared by first placing an SDA block measuring 1 cm × 1 cm × 1 cm onto a glass slide. Each surface of the agar block was inoculated with the conidia of HKU44^T (3×10^4 colony forming units) and a cover slip was then placed on top of the agar block. The slide culture was incubated at 25°C for 7 days after which the cover slip with the attaching fungal materials, mounted and stained with lactophenol cotton blue (BD Diagnostics System), was transferred on a fresh glass slide. Microscopic characteristics were observed using the microscope BX43 (Olympus, Japan) under an original magnification of 1000× and digital images were obtained by the attached camera DP80 (Olympus) and the software cellSens Dimension (Olympus). Measurement was made for 40–60 structures for each microscopic character. HKU44^T was also microscopically examined by scanning electron microscopy, performed following a simplified protocol [41]. Briefly, polycarbonate filter membranes with a pore size of 0.8 µm were placed on tap water agar (1.5% agarose [w/v; BD Diagnostic Systems]). Strain HKU44^T was then inoculated on the membranes and was incubated at 25°C for 14 days. Upon colony maturation, the culture was fixed using formalin vapour by adding 1 mL of 37% formaldehyde (in water, v/v; Sigma Aldrich, USA) onto the lid of the inverted Petri dish which was then securely sealed and incubated overnight. Membranes with fixed fungal materials were then collected and washed with absolute ethanol (Merck, Germany) twice and then sent to the Electron Microscope Unit of The University of Hong Kong for sample processing, where the fixed samples were dried by the critical point dryer CPD 030 (Bal-Tec, Liechtenstein) using liquid carbon dioxide as the transitional fluid, mounted on aluminium stubs and then coated with a thin layer (10–20 nm) of palladium for electrical conduction by the cool sputter coater SCD 005 (Bal-Tec). Coated specimens were then examined using the field emission scanning electron microscope S-4800 (Hitachi High-Technologies, Japan).

DNA extraction, ITS, partial 28S nrDNA, partial 18S nrDNA and partial β-tubulin gene sequencing, sequence identity analyses and phylogenetic analyses

Extraction of fungal DNA, polymerase chain reaction (PCR), and sequencing of the ITS, partial 28S nuclear ribosomal DNA (nrDNA), partial 18S nrDNA and partial β-tubulin gene for the case isolate HKU44^T and the ex-type/reference strains of other *Pleurostoma* species were carried out following our previous publication [42] with the primer pairs ITS1/ITS4 [43] for

the ITS, NL1/NL4 [44] for partial 28S nrDNA, NS1/NS4 [43] for partial 18S nrDNA as well as TUB2-F/TUB2-R [45] for partial β -tubulin gene. The DNA sequences obtained, together with those of other closely related species/strains accessioned in the DDBJ/ENA/GenBank databases, were then compared by pairwise alignment using BioEdit 7.2.0 [46]. These sequences were also analysed by multiple sequence alignment using MUSCLE 3.8 [47]. After end-trimming, divergent or poorly aligned regions of the DNA sequences were removed using Gblocks 0.91b [48, 49] with relaxed parameters. Test for substitution model and phylogenetic tree reconstruction for each DNA marker were performed by the maximum likelihood method using MEGA 6.0.6 [50]. Phylogenetic analyses included 531, 560, 822 and 397 nucleotide positions of the ITS, partial 28S nrDNA, partial 18S nrDNA and partial β -tubulin gene sequences, respectively. Phylogenetic trees were also reconstructed using the concatenated sequences of the four DNA markers (total 2340 nucleotide positions) of HKU44^T and other *Pleurostoma* strains by the maximum likelihood method as described above and by the Bayesian evolutionary analysis using BEAST 1.10.4 [51]. For Bayesian inference, ten million generations were run with trees sampled every 1000th generation to yield 10,000 trees. The trees, after a 10% burn-in, were summarized as a single tree using TreeAnnotator 1.8.0 by choosing the tree with the maximum sum of posterior probabilities (maximum clade credibility) and viewed using FigTree 1.4.0.

In vitro antifungal susceptibility test

The *in vitro* susceptibilities against 11 antifungal drugs, including amphotericin B (Cayman Chemical, USA), anidulafungin (SelleckChem, USA), caspofungin (TargetMol, USA), micafungin (TargetMol), fluconazole (TargetMol), isavuconazole (TargetMol), itraconazole (TargetMol), posaconazole (Sigma-Aldrich), ravuconazole (Sigma-Aldrich), voriconazole (TargetMol) and flucytosine (Sigma-Aldrich), were determined by the microbroth dilution method according to the guidelines by the European Committee on Antimicrobial Susceptibility Testing (EUCAST) (test range: 0.0156–8 μ g/mL for itraconazole and posaconazole; 0.0312–16 μ g/mL for other drugs) [52] and our previous publication [53]. For echinocandins, minimum effective concentration (MEC) endpoints were recorded as the lowest drug concentrations in which abnormal, short and branched hyphal clusters were observed; whereas for the other antifungal agents, minimum inhibitory concentration (MIC) endpoints yielding no visible fungal growth by eyes were recorded. Strains *Aspergillus flavus* ATCC 204304 and CNM-CM-1813, *Aspergillus fumigatus* ATCC 204305, *Candida albicans* CNM-CL F8555, *Candida parapsilosis* ATCC 22019^T as well as

Pichia kudriavzevii CNM-CL-3403 and NRRL Y-413 were used as quality controls.

Data availability

A dried specimen of the case isolate HKU44^T (the holotype) was deposited to UAMH whereas living cultures of HKU44^T were deposited to UAMH and the Culture Collection of Switzerland (CCOS). The ITS, partial 28S nrDNA, partial 18S nrDNA and partial β -tubulin gene sequences of HKU44^T and the ex-type/reference strains of other *Pleurostoma* species were deposited in the DDBJ/ENA/GenBank databases (Table S1).

Results

Patient

A 65-year-old Chinese man was admitted in March 2017 for management of post-liver transplant biliary stricture. The patient had hepatitis B virus-related liver failure and living donor liver transplantation was performed in November 2015. Biliary stricture developed and right hepatico-jejunostomy bypass was performed in August 2016. The patient developed stricture of the hepatico-jejunostomy bypass and was admitted in March 2017 for a second hepatico-jejunostomy bypass. Post-operatively, the patient developed increasing abdominal pain. Computed tomography examination of the abdomen revealed a 4.3 cm \times 0.8 cm collection with gas pocket and rim enhancement was observed around the tubal drains in the upper abdomen (Figure 1). Laparotomy was performed in May 2017 and a loculated abscess with 5 mL of pus was observed in the subhepatic space. Drainage of the abscess was performed. Biopsy of the abscess wall showed abundant fungal hyphae (Figure 2). Bacterial and fungal cultures of the pus recovered *Klebsiella pneumoniae*, *Enterococcus faecalis*, *Enterobacter cloacae* and a dematiaceous fungus (strain HKU44^T). Despite antimicrobial treatment including the use of anidulafungin, the same dematiaceous fungus was repeatedly recovered from the drain fluid eight more times. The patient developed progressive liver failure and cadaveric liver transplantation was performed again in July 2017. Post-operatively, amphotericin B and voriconazole were given for 16 days, followed by voriconazole maintenance therapy for three months. The function of the graft was normal and the dematiaceous fungus was not isolated from the patient again up to the time of writing, three years after the second liver transplantation.

Phenotypic characterizations

The colony macroscopy of HKU44^T varied greatly when cultured on different media. On MEA, colonies

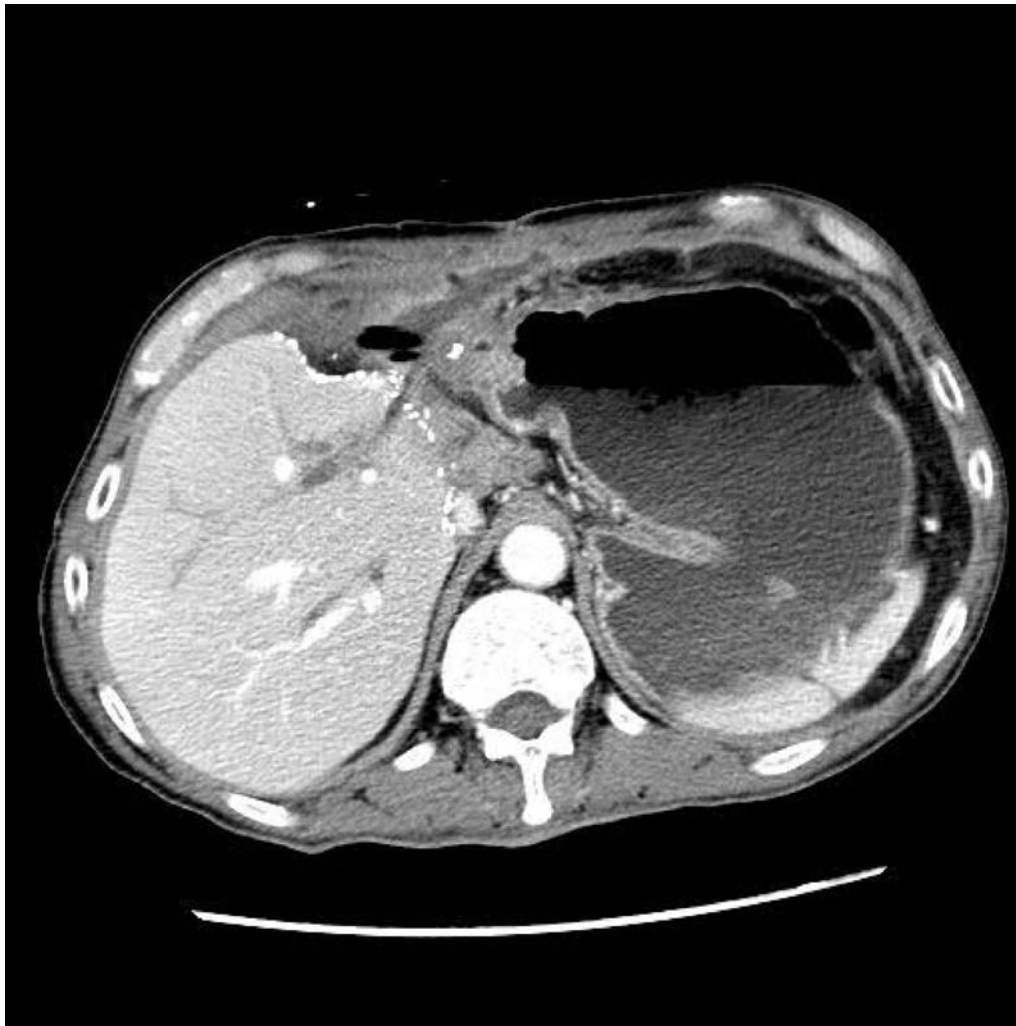

Figure 1. Computed tomography image of the upper abdomen. A small fluid collection with gas pocket was found and rim enhancement was observed around the tubal drains.

were grey with creamy mycelial tufts on the surface. The reverse was beige (Figure 3(a,d)). On SDA, HKU44^T initially grew white but developed a beige complexion on day 5. The colony surface was powdery but the outer colony border was floccose (Figure 3(b, e)). The reverse surface maintained the same coloration. Meanwhile on PDA, the colony surface was flat and creamy white. As the colony matured, a yellow pigment or hue appeared to diffuse from the initial point of inoculation, but remained confined to the mycelial mat (Figure 3(c,f)). Furthermore, short white creamy mycelial tufts began to emerge from the outer ring of the growing colony and later grew inwards as the colony matured. No diffusible pigment was observed for the fungus when cultured on all the three media tested. The growth rate of HKU44^T on the three media tested also differed. After 7 days of incubation at 25°C, HKU44^T grew significantly the fastest on PDA, attaining a colony diameter of approximately 50 mm; whereas on SDA and MEA the fungus grew slower, attaining colony diameters of around 35 mm and 31 mm, respectively (Figure S1(a)). In addition, growth of HKU44^T was influenced by temperature.

On SDA after 7 days of incubation, growth of HKU44^T at 25°C and 30°C was comparable, with colony diameters of around 30–40 mm. When the temperature increased to 35–37°C, the fungus grew significantly faster, attaining colony diameters of around 60 mm (Figure S1(b)).

Microscopically, hyphae were septate and hyaline and hyphal walls were verruculose (Figure 4). Phialides appeared to be monophaealidic, but were usually closely associated to a cluster of conidia and were usually laterally located rather than terminally on hyphae (Figure 4). Several distinguishable phialide structures were observed including swollen elongate-ampulliform phialides with constricted bases (Figure 4(a,d,g)), relatively long type I-like adelophaealides which lacked basal septa (Figure 4(b,e,h)) as well as shorter and indistinct projection-like conidiophores associated with spherical to ellipsoidal conidia (Figure 4(c,f,i)). Collarettes were usually inconspicuous, though slightly cupped or tubular collarettes could be observed for the longer and larger conidiophores (Figure 4(e,g,h)). Conidia sported a wide variety of shapes and sizes including spherical, oblong-elliptical,

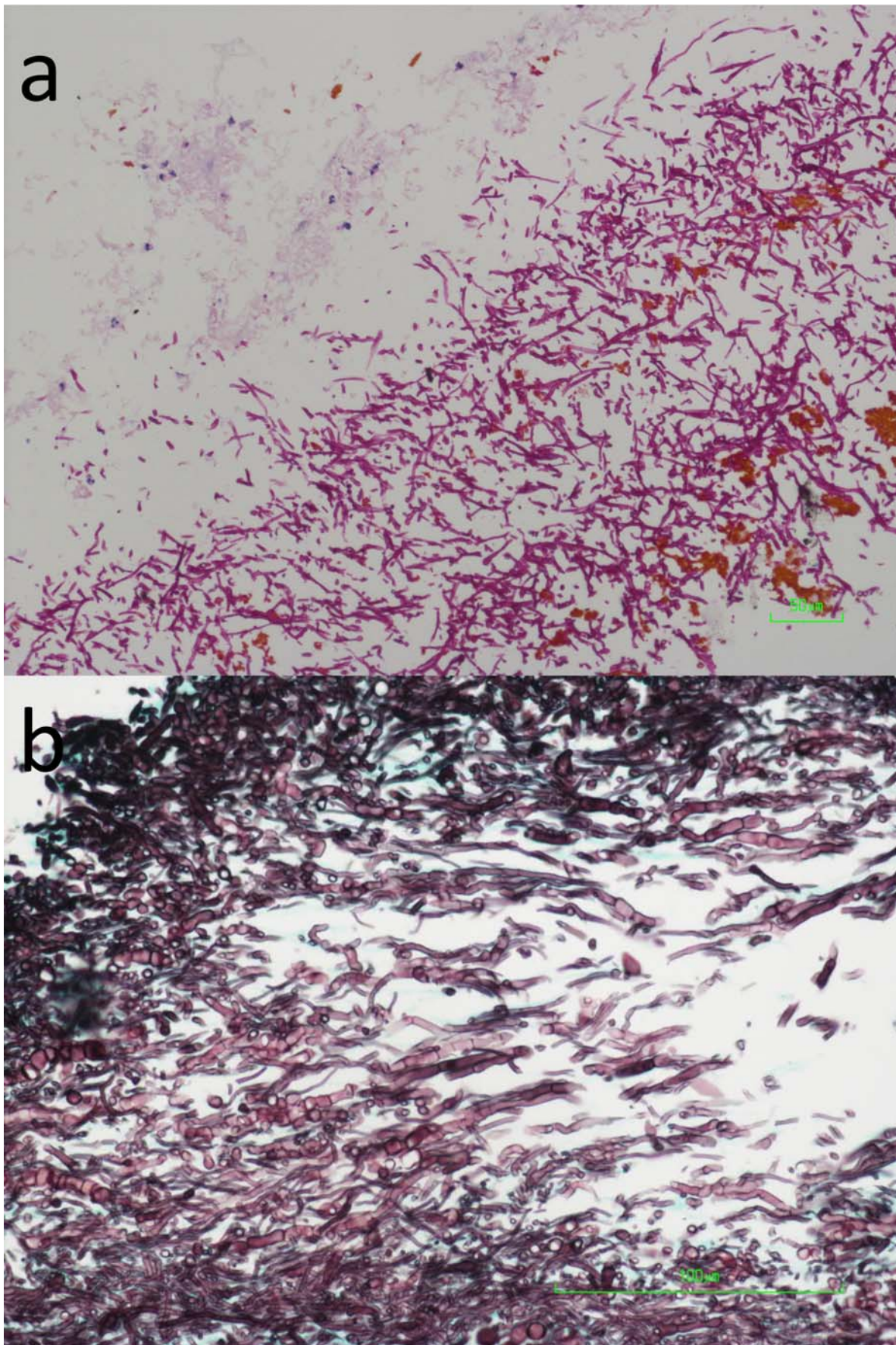


Figure 2. Photomicrographs of the biopsied liver abscess wall tissue. (a) Abundant fungal hyphae, a small amount of necrotic tissue, brown bile pigments as well as a few acute inflammatory cells were observed (Periodic acid-Schiff staining, original magnification 200×). (b) The fungal hyphae were highly septate (Grocott methenamine-silver staining, original magnification 400×).

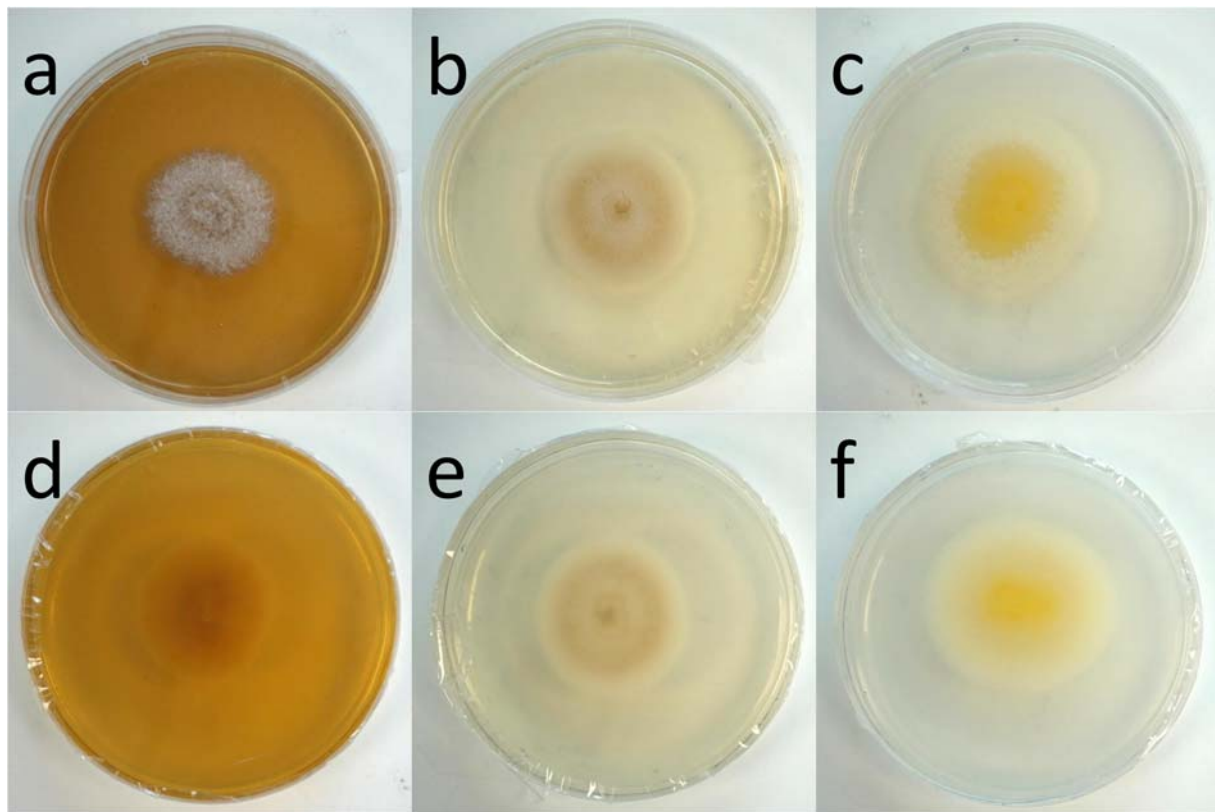


Figure 3. Growth of *Pleurostoma hongkongense* HKU44^T on various culture media after 7 days of incubation at 25°C. (a, d) Malt extract agar (MEA). (b, e) Sabouraud dextrose agar (SDA). (c, f) Potato dextrose agar (PDA). Brightness was adjusted individually for each panel.

allantoid and most commonly reniform. Notably, subspherical and oblong shaped conidia tended to associate more frequently with shorter conidiophores (Figure 4(c,f,i)), while reniform and allantoid conidia were found congregated to the other two types of conidiophores (Figure 4(a–h)).

Molecular characterizations

PCR of the ITS, partial 28S nrDNA, partial 18S nrDNA and partial β -tubulin gene of HKU44^T and the reference strains yielded DNA products with lengths of about 600, 600, 1100 and 500 bp, respectively. Pairwise alignment showed that the partial ITS sequence of HKU44^T possessed an 88.9% identity to *Pleurostoma ootheca* CBS 115329, an 88.6% identity to *Pleurostoma repens* CBS 294.39^T, an 87.3% identity to *Pleurostoma richardsiae* CBS 270.33^T and an 86.5% identity to *Pleurostoma ochraceum* CBS 131321^T. The partial 28S nrDNA sequence of HKU44^T possessed a 98.8% identity to *Pleurostoma ootheca* CBS 115329, a 98.2% identity to *Pleurostoma repens* CBS 294.39^T, a 97.9% identity to *Pleurostoma richardsiae* CBS 270.33^T and a 95.9% identity to *Pleurostoma ochraceum* CBS 131321^T. The partial 18S nrDNA sequence of HKU44^T possessed a 99.5% identity to *Pleurostoma richardsiae* CBS 270.33^T, a 99.4% identity to *Pleurostoma ootheca* CBS 115329 and *Pleurostoma repens*

CBS 294.39^T and a 99.0% identity to *Pleurostoma ochraceum* CBS 131321^T. The partial β -tubulin gene sequence of HKU44^T possessed an 80.1% sequence identity to *Pleurostoma repens* CBS 294.39^T, a 79.1% sequence identity to *Pleurostoma ootheca* CBS 115329, a 78.8% identity to *Pleurostoma richardsiae* CBS 270.33^T and a 76.6% sequence identity to *Pleurostoma ochraceum* CBS 131321^T. Phylogenetic analyses showed that HKU44^T occupied a unique phylogenetic position in the ITS, partial 28S nrDNA, partial 18S nrDNA and partial β -tubulin gene trees (Figure S2) by the maximum-likelihood method as well as in the concatenated sequence trees by both the maximum-likelihood method and Bayesian evolutionary analysis (Figure 5). Although HKU44^T is most closely related to *Pleurostoma ootheca* and *Pleurostoma repens*, it is distinct from all the *Pleurostoma* species characterized, suggesting it is a novel *Pleurostoma* species.

In vitro antifungal susceptibilities

The *in vitro* susceptibilities of HKU44^T and other *Pleurostoma* strains to 11 different antifungal agents are listed in Table 1. HKU44^T possessed high MICs/MECs (>8 μ g/mL) to all antifungal agents tested except amphotericin B (0.5 μ g/mL). As for other *Pleurostoma* strains, all of them had high MICs to flucytosine and fluconazole (\geq 4 μ g/mL) and most

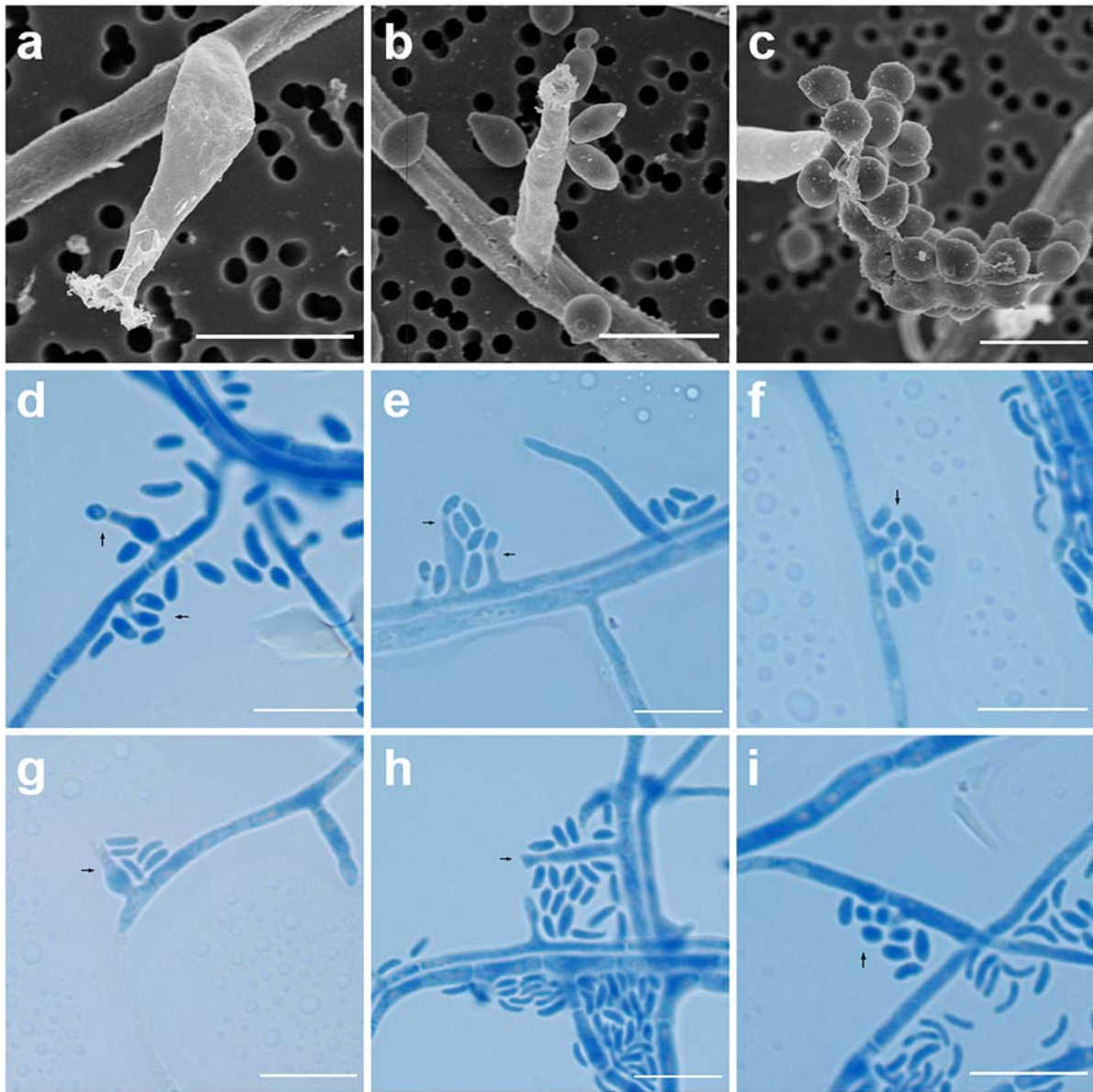


Figure 4. Microscopic features of *Pleurostoma hongkongense* HKU44^T. Arrows indicate notable structures. (a–c) Scanning electron microscopy photographs of notable phialide and conidia features. Scale bars = 5 µm. (d–i) Bright-field microscopy of corresponding features using a slide culture preparation. Slides were prepared via wet mount and stained with lactophenol cotton blue (original magnification 1000×). Scale bars = 10 µm.

had high MECs (≥ 2 µg/mL) to the echinocandins, except *Pleurostoma ochraceum* CBS 131321^T and *Pleurostoma richardsiae* NCPF 2765 which had low MECs (0.5 and 1 µg/mL, respectively) to caspofungin. In addition to fluconazole, in general these *Pleurostoma* strains possessed high MICs to other triazole agents as well. Only ten of them possessed low MICs (≤ 1 µg/mL) to posaconazole, seven to itraconazole, four to voriconazole and three to each of isavuconazole and ravuconazole. On the contrary, the majority of other *Pleurostoma* strains tested possessed low MICs (≤ 1 µg/mL) to amphotericin B, including *Pleurostoma repens* CBS 294.39, *Pleurostoma ochraceum* CBS 131321^T, *Pleurostoma ootheca* CBS 115329 and 14 strains of *Pleurostoma richardsiae*.

Taxonomy

Pleurostoma hongkongense, C.-C. Tsang, K.-F. Chan, W. Chan, J.F.W. Chan, R.K.H. Au-Yeung, A.H.Y. Ngan, K.P.K. Lin, S.K.P. Lau, P.C.Y. Woo, sp. nov.

Mycobank accession number: MB 835850.

Etymology: of or belonging to Hong Kong, the place where the holotype was isolated.

Colonies on MEA grey, with creamy mycelial tufts and a beige reverse, reaching ~31 mm in diameter after 7 days of incubation at 25°C. Colonies on SDA initially white, turning beige after 5 days of incubation, powdery, with a floccose border and same-coloured reverse, reaching ~30–40 mm in diameter after 7 days of incubation at 25–30°C, and around 60 mm in diameter at 35–37°C. On PDA, colonies flat and

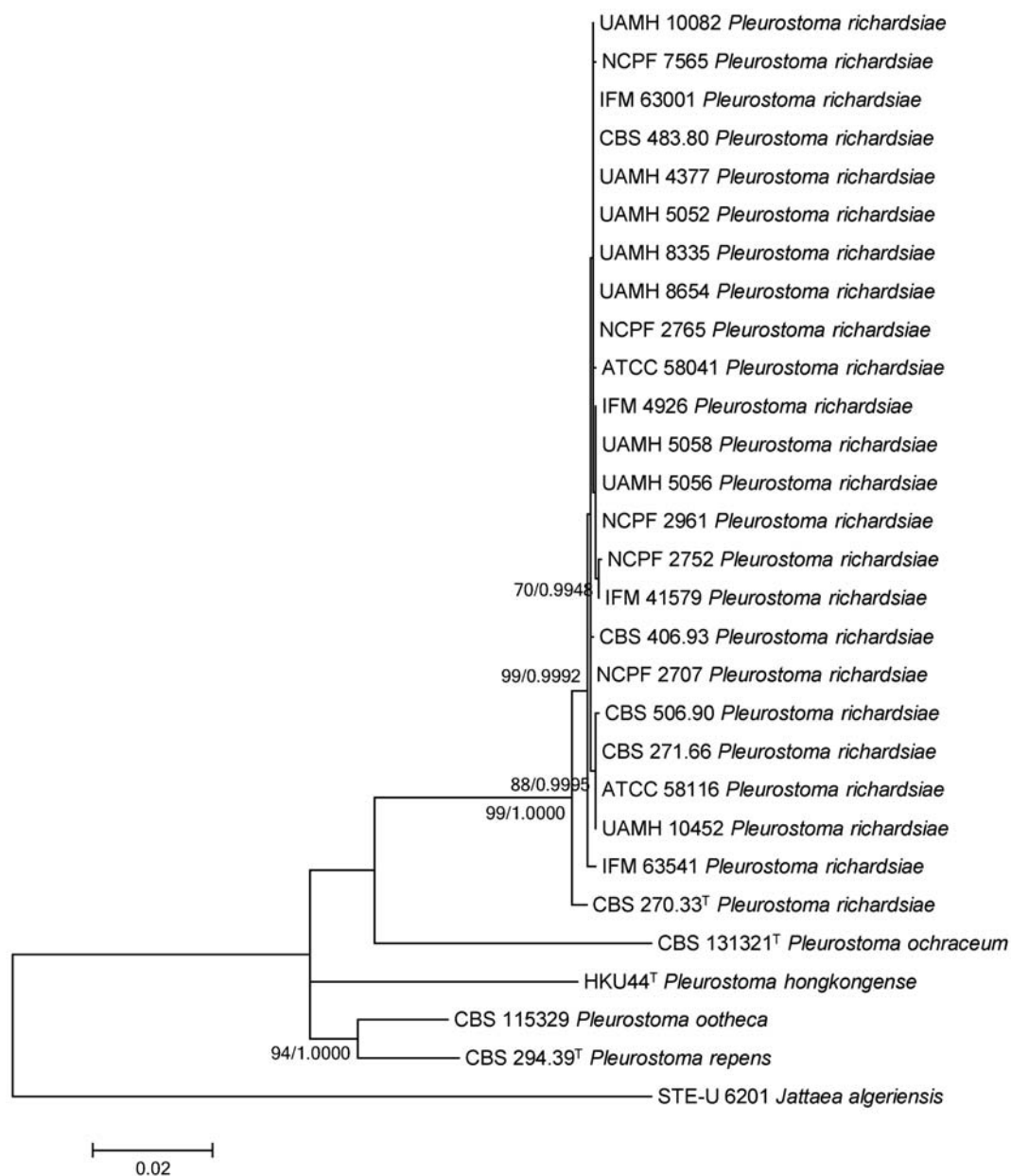


Figure 5. Phylogenetic tree showing the relationship of *Pleurostoma hongkongense* HKU44^T to its closely related species within the genus *Pleurostoma*. The tree was inferred from the concatenated sequence data of the internal transcribed spacer (ITS) region, partial β -tubulin gene, partial 18S nrDNA and partial 28S nrDNA by the maximum likelihood method with the substitution model T92 (Tamura 3-parameter model) + G (gamma-distributed rate variation) + I (estimated proportion of invariable sites). The scale bar indicates the estimated number of substitutions per base. Only nodes that were well supported by the maximum-likelihood method ($\geq 70\%$ bootstrap support) have their bootstrap support, calculated from 1,000 replicates, shown; and all these nodes were also well supported by the Bayesian inference method (posterior probabilities ≥ 0.99). The DDBJ/ENA/GenBank nucleotide accession numbers for *Jattaea algeriensis* STE-U 6201^T are EU367446 (ITS), EU367466 (β -tubulin), EU367462 (18S nrDNA) and EU367456 (28S nrDNA).

creamy white, with a yellow hue at the centre and short, white creamy mycelial tufts emerging from the rims upon maturation, reaching ~ 50 mm in diameter after 7 days of incubation at 25°C.

Hyphae 1.3–6.5 μm ($\bar{x} = 2.5 \pm 0.9$ μm , $n = 58$) wide, septate and hyaline, with verruculose walls. Phialides 1.5–11.0 $\mu\text{m} \times 0.7$ –3.0 μm ($\bar{x} = 4.7 \pm 2.7$ $\mu\text{m} \times 1.7 \pm 0.5$ μm , $n = 42$), monopialidic, usually laterally located and closely associated to a cluster of conidia. Three types of phialide structures were observed,

including swollen elongate-ampulliform phialides with constricted bases, relatively long type I-like adelphialides which lacked basal septa as well as shorter and indistinct projection-like conidiophores associated with spherical to ellipsoidal conidia. Collarettes inconspicuous, though slightly cupped or tubular collarettes were observable for the longer and larger conidiophores. Conidia 0.3–11.0 $\mu\text{m} \times 1.5$ –3.7 μm ($\bar{x} = 2.6 \pm 0.4$ $\mu\text{m} \times 2.7 \pm 0.6$ μm , $n = 49$), most commonly reniform, occasionally spherical, oblong-elliptical or

Table 1. Minimum inhibitory concentrations (MICs) or minimum effective concentrations (MECs) of different antifungal agents against *Pleurostoma* species.^a

Species	Strain	MICs/MECs (µg/mL)										
		Triazoles				Echinocandins			Others			
		FLC	ISA	ITC	POS	RAV	VRC	AFG	CAS	MFG	5FC	AMB
<i>P. hongkongense</i>	HKU44 ^T	>16	>16	>8	>8	>16	16	>16	16	>16	>16	0.5
<i>P. repens</i>	CBS 294.39 ^T	16	1	0.5	0.5	1	0.25	4	2	16	>16	0.25
<i>P. richardsiae</i>	ATCC 58041	>16	4	>8	1	4	2	>16	16	>16	>16	1
	ATCC 58116	>16	>16	>8	>8	>16	>16	>16	16	>16	>16	2
	CBS 270.33 ^T	>16	1	0.5	0.25	1	2	4	8	>16	>16	0.5
	CBS 271.66	>16	2	0.5	2	2	4	>16	16	>16	>16	1
	CBS 406.93	>16	>16	>8	>8	>16	>16	>16	16	>16	>16	2
	CBS 483.80	>16	>16	>8	>8	>16	>16	>16	>16	>16	>16	2
	CBS 506.90	>16	4	8	1	8	2	>16	4	>16	>16	2
	IFM 4926	>16	4	1	1	4	2	>16	16	>16	>16	1
	IFM 41579	>16	4	>8	8	4	4	2	8	>16	>16	1
	IFM 63001	>16	>16	>8	>8	>16	>16	>16	16	>16	>16	2
	IFM 63541	>16	>16	8	8	16	>16	4	8	2	>16	1
	UAMH 4377	>16	2	1	1	2	1	>16	16	>16	>16	1
	UAMH 5052	>16	>16	>8	>8	>16	>16	>16	8	>16	>16	1
	UAMH 5056	>16	2	1	1	4	4	>16	16	>16	>16	0.5
	UAMH 5058	>16	2	>8	>8	>16	1	4	4	>16	>16	1
	UAMH 8335	>16	>16	>8	>8	>16	8	>16	8	>16	>16	2
	UAMH 8654	>16	>16	>8	>8	>16	>16	>16	16	>16	>16	2
	UAMH 10082	>16	16	>8	>8	>16	16	>16	8	>16	>16	2
	UAMH 10452	>16	16	8	8	16	16	>16	8	>16	>16	1
	NCPF 2707	>16	8	>8	8	4	8	>16	2	>16	>16	1
NCPF 2752	>16	4	2	1	4	4	>16	16	>16	>16	2	
NCPF 2765	>16	>16	>8	>8	>16	>16	>16	1	>16	>16	4	
NCPF 2961	>16	8	>8	8	4	2	>16	8	>16	>16	1	
NCPF 7565	>16	>16	>8	>8	>16	>16	>16	4	>16	>16	1	
<i>P. ochraceum</i>	CBS 131321 ^T	4	0.5	0.25	0.25	0.5	0.5	4	0.5	4	>16	1
<i>P. ootheca</i>	CBS 115329	>16	16	>8	1	8	8	>16	8	>16	>16	1

^aAFG, anidulafungin; AMB, amphotericin B; CAS, caspofungin, FLC, fluconazole; ISA, isavuconazole; ITC, itraconazole; MFG, micafungin; POS, posaconazole; RAV, ravuconazole; VRC, voriconazole; 5FC, flucytosine.

allantoid. Subspherical and oblong shaped conidia usually associated with shorter conidiophores and reniform and allantoid conidia usually congregated to the other two types of conidiophores.

Holotype: UAMH 12185. Ex-type culture: HKU44^T (= CCOS 1933^T = UAMH 12185^T).

Pleurostoma hongkongense may be phenotypically difficult to differentiate from other *Pleurostoma* species due to the high variability observed in the conidiophore and conidia characteristics of each species (Table 2). Furthermore, colony age and maturity are also the confounding factors for microscopic identification. The asexual morphs of members of *Pleurostoma* are monophialidic and heavily sporulating. *Pleurostoma richardsiae* is likely the easiest to differentiate, as its conidia are most commonly spherical and aggregate as slimy masses at the apices of distinct flared collarettes (Figure S3(a)). The wide saucer shaped collarette observed in *Pleurostoma richardsiae* is not observed in other *Pleurostoma* species, which usually display either cupped or slightly rounded collarettes. *Pleurostoma repens* can be differentiated through its relatively long, branched and elongated conidiophores. In addition, spherical conidia have never been observed in *Pleurostoma repens*. *Pleurostoma ootheca* were observed to have the shortest phialides. In addition, spherical conidia were found to be tightly bunched at the apices of these short phialides (Figure S3(b)). *Pleurostoma ochraceum* and *Pleurostoma hongkongense* share remarkably similar

phialide and hyphal structures, but a large noticeable difference is the degree of melanization of conidia. *Pleurostoma ochraceum* has distinctly melanized and thick-walled spherical conidia (Figure S3(c)). The asexual morph of *P. candollei* is not known [2].

Discussion

We report the isolation of HKU44^T from the subhepatic abscess as well as repeatedly from the drain fluid eight more times in a liver transplant recipient, who received prednisolone and tacrolimus that had suppressed his immune system, rendering him susceptible to invasive fungal infections. The clinical significance of the fungus was evident by the invasion of the fungus to the patient's tissue as demonstrated by the presence of abundant fungal hyphae as well as necrotic tissue and acute inflammatory cells in histological sections of the biopsied specimen. Culture of the abscess pus and drain fluid specimens also showed colonies at the primary inoculum on all agar plates inoculated with the specimens, supporting that the isolate was from the clinical specimens, instead of due to environmental contamination. Sequencing of four different DNA regions commonly used for phylogenetic studies, including the ITS, partial 28S nrDNA, partial 18S nrDNA and partial β -tubulin gene [54], and phylogenetic analyses showed that HKU44^T stood out as a unique branch distinct from the other *Pleurostoma*

Table 2. Microscopic features of different *Pleurostoma* species during asexual life cycles.

Species	Hyphae	Phialides	Conidia
<i>P. hongkongense</i>	2–6 µm wide, septate, verruculose, and hyaline	3–30 µm long, phialide variety similar to <i>P. ochraceum</i>	Microconidia 2–8 µm long, spherical, ellipsoidal or oblong; macroconidia most commonly allantoid and reniform
<i>P. repens</i>	2–4 µm wide, septate, smooth and initially hyaline, pale brown when matured	6–30 µm long, inconspicuous, slightly flared collarettes on elongated phialides, conidiophores often branched	3–6 µm long, cylindrical to allantoid only
<i>P. richardsiae</i>	2–4 µm wide, septate and smooth when young, heavily septated, thick-walled and brown when matured	10–35 µm long, flask shaped with distinct saucer-shaped flared collarette at apex	2–6 µm long, commonly spherical or ellipsoidal
<i>P. ochraceum</i>	1.2–3.2 µm wide, branched, septate, smooth and verruculose	6–20 µm long, three types of phialides described: type 1 adelophialides, type 2 elongate-ampulliform, and larger, longer type 3 cylindrical/ampulliform phialides	1.5–6 µm long, melanised sub-spherical or ellipsoidal
<i>P. ootheca</i>	1.8–3.3 µm wide, septate and hyaline	6–19 µm long, inconspicuously flared collarettes, short phialides	3–6 µm long, most commonly oblong, straight, or allantoid; shorter and ellipsoid conidia also present

The asexual morph of *P. candollei* is not known [2]. Data for *P. hongkongense* were obtained in this study, data for the other *Pleurostoma* species were cited from the literature [18, 26, 55].

species in the concatenated trees (Figure 5) as well as all the individual DNA marker trees (Figure S2), despite being the most closely related to *Pleurostoma ootheca* and *Pleurostoma repens*. HKU44^T also possessed morphological features different to those of other known *Pleurostoma* species (Figure 4 and Figure S3). All these results supported that HKU44^T should belong to a novel *Pleurostoma* species distinct from any other member of this genus, and we propose a novel species, *Pleurostoma hongkongense*, to accommodate HKU44^T.

In addition to the discovery of a novel *Pleurostoma* species, the present case also represents the first case of *Pleurostoma* subhepatic abscess in a liver transplant

recipient. Among all the 37 cases of *Pleurostoma* infections reported, 33 (89.2%) were caused by *Pleurostoma richardsiae*, and the remaining four cases were due to *Pleurostoma hongkongense*, *Pleurostoma ochraceum*, *Pleurostoma ootheca* and *Pleurostoma repens*, respectively. For predisposing factors, more than 70% of *Pleurostoma* infections have major underlying diseases (Table 3). The commonest medical conditions leading to systemic immunosuppression are diabetes mellitus (33.3%), malignancies (18.5%) and renal transplant (18.5%). Of all the 37 cases, 27 (73.0%) had infections (osteomyelitis, cutaneous/subcutaneous nodules, masses, lesions, cysts or abscesses, bursitis, cellulitis, eumycetoma and chromoblastomycosis) of the extremities, with 18 cases (66.7%) involving the lower limbs only, six (22.2%) infecting the upper limbs only and three (11.1%) affecting both upper and lower extremities. The portal of entry of the fungus is believed to be direct inoculation of the dematiaceous fungus through the skin as a result of unnoticed minor trauma. *Pleurostoma* infection has only been reported in one other liver transplant recipient (Case 35, Table 3), who was a 57-year-old Thai man with disseminated phaeohyphomycosis and hepatic artery and portal vein thrombosis due to *Pleurostoma richardsiae* [40]. The fungus was recovered from the patient's blood as well as the blood clot from the failed liver graft. Identification of the fungus was achieved through ITS sequencing. On the other hand, our present case had surgical site infection with subhepatic space infection. Although the route of infection cannot be ascertained, we speculate that the fungus has invaded through the wound of the surgical site and settled in the subhepatic space.

DNA sequencing should be performed to accurately identify *Pleurostoma* species from fungal cultures with *Pleurostoma*- or *Phialophora*-like morphologies. Microscopically, *Pleurostoma* species are characterized by the possession of *Phialophora*-like single, separate, hyaline to pigmented, monophialidic, short conidiophores with inconspicuous or flaring collarettes producing smooth, hyaline, dimorphic conidia, either straight to allantoid or short and ellipsoid, aggregated as slimy masses at the apices of conidiogenous cells during their asexual life cycles [55]. However, identification to the species level is best performed by DNA sequencing of one or more conserved markers, especially the ITS region [9–11, 25–27, 29, 30, 38, 40]. Notably, two early cases of subcutaneous nodules were originally reported as *Pleurostoma repens*-associated based on morphological identification of the filamentous fungi isolated [56, 57]. However, subsequent molecular studies revealed that the two fungal isolates were actually *Phaeoacremonium krajdenii* instead [58]. As for MALDI–TOF MS, although it has been increasingly used for the rapid identification of filamentous fungi

Table 3. Infections caused by *Pleurostoma* species.

Case	Sex ^{a/} Age (year)	Ethnicity	Underlying medical conditions	Clinical syndrome	Isolation source	Fungal species	Antifungal treatment	Outcome	Reference
1	M/80	American	Congestive heart failure	Subcutaneous cystic mass on proximal interphalangeal joint of left fifth finger	Cyst fluid	<i>P. richardsiae</i>	Surgical excision	Remission	[12]
2	F/50	German	Not mentioned	Dacryocystitis	Lacrimal sac stone	<i>P. richardsiae</i>	Surgical excision	Remission	[36]
3	M/79	African	None	Chronic bursitis on right elbow	Cystic mass	<i>P. richardsiae</i>	Surgical excision	Remission	[31]
4	M/65	American	Diabetes mellitus	Right foot sole lesion	Purulent fluid from lesion	<i>P. richardsiae</i>	Surgical excision and drainage	Remission	[13]
5	M/43	American	Diabetes mellitus, adrenocortical carcinoma, multiple hepatic metastases	Ulcerative lesion on right leg	Lesion discharge	<i>P. richardsiae</i>	Not mentioned	Deceased	[13]
6	M/52	American	None	Subcutaneous lesion on left index finger	Subcutaneous mass	<i>P. richardsiae</i>	Surgical excision	Remission	[7]
7	F/70	American	Myeloproliferative disease	Osteomyelitis of right foot	Bone	<i>P. richardsiae</i>	Debridement of infected bone, amphotericin B for 1 week followed by flucytosine for 2.5 weeks	Deceased due to subsequent disseminated <i>Nocardia</i> infection	[32]
8	M/54	American	Tendinitis, received methylprednisolone injection	Subcutaneous mass on right dorsal index finger	Not mentioned	<i>P. richardsiae</i>	Surgical excision	Not mentioned	[14]
9	M/30	Malaysian	Left femur fracture with skeletal traction and intramedullary nailing	Cutaneous lesions over left lower tibia & ankle	Lesion biopsy	<i>P. richardsiae</i>	Oral griseofulvin and topical naftifine for three weeks, surgical excision five months after recurrence	Persisted for two more months and then lost to follow-up	[15]
10	M/47	French	Hepatitis B virus carrier, recurrent duodenal ulcer	Cutaneous nodule at right patella	Cystic mass biopsy	<i>P. richardsiae</i>	Surgical excision	Remission	[16, 20]
11	M/30	Senegalese	Non-Hodgkin's lymphoma, steroid-induced diabetes mellitus, osteoporosis	Subcutaneous abscess on right dorsal foot	Pus	<i>P. richardsiae</i>	Oral flucytosine, topical amphotericin B & surgical excision	Deceased due to disseminated intravascular coagulation	[17]
12	F/60	American	Hypertension, diabetes mellitus, atherosclerotic heart disease, obesity	Subcutaneous cystic nodule on left medial foot	Cyst aspirate	<i>P. richardsiae</i>	Surgical excision	Remission	[18]
13	M/64	Australian	Polymyalgia rheumatica, on prednisone & azathioprine therapy	Cutaneous nodules on right knee, right thigh and elbows	Skin biopsy	<i>P. richardsiae</i> & <i>Exophiala jeanselmei</i>	Oral flucytosine for 10 days, then ketoconazole for 1 week, then itraconazole for 3 months	Remission	[19]
14	M/39	French	Renal transplant	Knee bursitis	Not mentioned	<i>P. richardsiae</i>	Surgical drainage and antifungal therapy, then surgical excision after recurrence	Not mentioned	[20]
15	F/15	Indian	None	Cutaneous lesion near waistline	Skin scrapings & biopsy	<i>P. richardsiae</i>	Topical clotrimazole for 15 days	Remission	[8]
16	F/50	Indian	None	Cutaneous lesion near waistline	Skin scrapings & biopsy	<i>P. richardsiae</i>	Topical clotrimazole for 15 days	Remission	[8]
17	M/52	British	Diabetes mellitus, porcine mitral valve replacement	Endocarditis & fungaemia	Blood, aortic & porcine mitral valves	<i>P. richardsiae</i>	Aortic and mitral valves replacement, amphotericin B for nearly 6 weeks	Deceased	[39]
18	M/54	British Afro-Caribbean	Renal transplant, hypertension, steroid-induced diabetes mellitus	Cutaneous lesions on right ring finger & left knee	Pus	<i>P. richardsiae</i>	Surgical excision	Remission	[21]

(Continued)

Table 3. Continued.

Case	Sex ^{a/} Age (year)	Ethnicity	Underlying medical conditions	Clinical syndrome	Isolation source	Fungal species	Antifungal treatment	Outcome	Reference
19	M/28	French	HIV, hepatitis C, intravenous drug use, tuberculosis, orthopaedic reconstructive surgery of right foot	Osteomyelitis	Bone aspirates of left elbow & left foot	<i>P. richardisiae</i>	Amphotericin B and flucytosine followed by itraconazole	Not mentioned	[33]
20	M/41	American	Surgical left ankle bone chip removal	Left ankle osteomyelitis	Surgical debridement specimens	<i>P. repens</i>	Surgical debridement, amphotericin B, oral ketoconazole for several months	Remission	[34]
21	M/36	American	Metallic intraocular foreign body	Right eye endophthalmitis	Vitreous samples	<i>P. richardisiae</i>	Pars plana vitrectomy and ketoconazole, followed by a repeat vitrectomy with intraocular lens removal, intravitreal amphotericin B and miconazole	Recurred after 12 months post-second vitrectomy	[37]
22	M/77	American	None	Septic infrapatellar bursitis & contiguous cellulitis	Bursal & superficial pustule aspirates, skin punch biopsy	<i>P. richardisiae</i>	Intravenous amphotericin B for 2 weeks, followed by oral itraconazole for 3 months	Remission	[22]
23	M/45	New Zealander	Renal transplant, transplant-related diabetes mellitus	Subcutaneous left foot abscess	Lesion aspirates, tissues	<i>P. richardisiae</i>	Surgical excision and liposomal amphotericin B for 1 week, repeat debridement & liposomal amphotericin B for 2 weeks followed by itraconazole for 6 weeks after recurrence	Remission	[23]
24	M/59	Japanese	Liver cirrhosis, hepatocellular carcinoma, hepatitis C	Eumycetoma on left foot	Lesion biopsy	<i>P. richardisiae</i>	Surgical excision	Remission	[24]
25	M/43	Korean	None	Right shin chromoblastomycosis	Skin tissue biopsy	<i>P. richardisiae</i>	Oral itraconazole 3 months, then combined with terbinafine for 3 months	Remission	[25]
26	M/60	Sudanese	None	Yellow-grain eumycetoma on right foot	Grains	<i>P. ochraceum</i>	Surgical debulking	Lost to follow-up	[26]
27	M/54	Canadian	None	Subcutaneous nodule on right patella & prepatellar bursitis	Prepatellar fluid aspirate	<i>P. richardisiae</i>	Therapy declined by patient	Lost to follow-up	[9]
28	M/59	Martinican	Renal transplant	Left ankle abscess	Cutaneous tissue	<i>P. ootheca</i>	Itraconazole for 1.5 months, then posaconazole for 2 months	Remission	[27]
29	M/43	American	Alcoholic cardiomyopathy, porcine mitral valve replacement, intravenous drug abuse, on systemic corticosteroid therapy	Endogenous endophthalmitis of right eye associated with osteomyelitis and endocarditis	Vitreous biopsy	<i>P. richardisiae</i>	Intravitreal amphotericin B during initial diagnostic vitrectomy, topical natamycin & intravenous amphotericin B, intravenous voriconazole added later, followed by repeat vitrectomy and intravitreal amphotericin B	Deceased due to massive intracranial haemorrhage	[35]
30	F/75	Dutch Chinese	Diabetes mellitus, chronic kidney disease, rheumatoid arthritis	Left arm infection	Pus and wound	<i>P. richardisiae</i>	Voriconazole for 6 months, repeated surgical eradication, discontinuation of immunosuppression	Deceased due to subsequent progressive multifocal leukoencephalopathy due to <i>Human polyomavirus 2</i> reactivation	[28]
31	M/78	Japanese	Diabetes mellitus, prostate & bladder cancers, myelodysplastic syndrome	Subcutaneous cyst on right crus	Pus	<i>P. richardisiae</i>	Local heat therapy with disposable chemical pocket warmers for 2 months, then combined with intracutaneous amphotericin B for 3 months	Deceased due to cancers	[29]
32	F/35	Indian	None	Periactinal mass	Periactinal mass	<i>P. richardisiae</i>	Surgical excision	Remission	[10]

33	M/72	Turkish	Papillary urothelial carcinoma	Perilacrimal organised lesion with transient nasolacrimal duct obstruction	Urinary tract infection	Urine	<i>P. richardsiae</i>	Amphotericin B for 4 days followed by itraconazole for 14 days	Remission	[38]
34	M/78	Spaniard	None	Subcutaneous cyst nodule on right dorsal hand	Urinary tract infection	Cyst biopsy	<i>P. richardsiae</i>	Therapy declined by patient	Not mentioned	[30]
35	M/57	Thai	Hepatitis B virus-related cirrhosis, liver transplant	Fungaemia associated with hepatic artery and portal vein thrombosis	Blood and liver blood clot	Blood and liver blood clot	<i>P. richardsiae</i>	Second liver transplant, amphotericin B for 4 weeks	Remission	[40]
36	M/74	Singaporean Chinese	Renal transplant, bronchiectasis	Subcutaneous thigh nodules	Subcutaneous thigh nodules	Skin biopsy and pus	<i>P. richardsiae</i>	Surgical excisions, itraconazole for 10 months	Remission	[11]
37	M/65	Hong Kong Chinese	Hepatitis B virus-related liver failure, liver transplant	Progressive liver failure	Progressive liver failure	Subhepatic abscess pus and drain fluids	<i>P. hongkongense</i>	Second liver transplant, amphotericin B and voriconazole	Remission	Present case

^aF, female; M, male.

Note: The fungal strains (UTMB 184 = CBS 423.75 [60] and SM 3531 = ATCC 58115 = BB 903 = CBS 110366 [56, 57]) isolated from two reported cases of *Pleurostoma repens* were subsequently reidentified as *Phaeoacremonium kraidenii* by molecular studies [58].

in clinical microbiology laboratories, use of this technology for *Pleurostoma* identification is still not possible since reference protein mass spectra for *Pleurostoma* species are still lacking in the databases by the two major commercial platforms (Bruker Daltons and Vitek, bioMérieux). Moreover, our attempt of MALDI-TOF MS analysis using the Bruker Daltons platform for our case isolate HKU44^T as well as other reference *Pleurostoma* strains also failed in generating interpretable protein mass spectra for database matching, probably due to difficulties in extracting cellular proteins during formic acid digestion. An optimal protein extraction protocol for sample preparation and expansion of the reference mass spectral libraries will be essential before MALDI-TOF MS could be utilized for the rapid identification of *Pleurostoma* species.

Treatment of *Pleurostoma* infections is often achieved by a combination of surgical excision/debridement of the infected tissue and antifungal therapy. Of the 37 cases of *Pleurostoma* infections, 25 (67.6%) required surgery to remove the infected tissue and 22 (59.4%) involved the administration of antifungals (Table 3). For the present patient as well as the previous liver transplant recipient, they were both treated successfully with a second liver transplant and antifungal agents. As for the choice of antifungal agents, almost all the *Pleurostoma* strains tested in the present study had high MICs/MECs to fluconazole, 5-flucytosine and the echinocandins (Table 1). For amphotericin B, 18 (64.3%) of the 28 *Pleurostoma* strains tested, including our case isolate *Pleurostoma hongkongense* HKU44^T, had MICs of ≤ 1 $\mu\text{g}/\text{mL}$, which is the general breakpoint for *Candida* species, *Cryptococcus neoformans*, *Aspergillus fumigatus* and *Aspergillus niger* [59]. As for the susceptibilities to the other triazoles, the results showed a high strain-to-strain variability (Table 1). In general, a strong Spearman correlation among the susceptibilities to different triazoles can be observed (Table S2). In view of the highly variable antifungal susceptibility profiles for *Pleurostoma* species and strains, MICs/MECs should be determined for deciding the optimal treatment regimen for individual patients. Remarkably, for the 36 *Pleurostoma* infection cases previously reported, seven of the isolates recovered were included in this study for susceptibility testing (ATCC 58041 [32], CBS 506.90 [8], CBS 131321^T [26], UAMH 5052 [13], UAMH 5056 [12], UAMH 5058 [13] and UAMH 10082 [23]). Amongst these seven cases, antifungal therapies were only administered for three of the patients (Case 7, ATCC 58041 [32]; Case 16, CBS 506.90 [8] and Case 23, UAMH 10082 [23] in Table 3). For Case 7, the patient was treated with the debridement of infected bone and amphotericin B prescription for one week followed by flucytosine prescription for two and a half weeks [32], although susceptibility testing in this

study showed that the isolate ATCC 58041 possessed MICs of 1 µg/mL and >16 µg/mL for these two antifungals, respectively. Similarly, for Case 23, the patient was first treated with surgical excision and prescription of liposomal amphotericin B for one week. However, due to recurrence a repeat debridement was performed and liposomal amphotericin B for two weeks followed by itraconazole for six weeks was prescribed [23]. Again, susceptibility testing in this study showed that isolate UAMH 10082 possessed high MICs of 2 µg/mL and >8 µg/mL for these two antifungals, respectively. For Case 16, the patient was treated with clotrimazole for 15 days [8]. Susceptibility to this drug was not tested in the present study and therefore, the activity of this drug to the fungal isolate (CBS 506.90) remains unknown. As for the present reported case due to *Pleurostoma hongkongense*, the patient was treated with antimicrobials including anidulafungin before the second liver transplant. However, this was not successful in curing the infection which may be partly due to a high MEC for anidulafungin (>16 µg/mL) for HKU44^T. After the second liver transplant, the patient was treated with amphotericin B and voriconazole while HKU44^T possessed MICs of 0.5 and 16 µg/mL for these two drugs, respectively. As a result, antifungal susceptibility testing should be performed for *Pleurostoma* species to guide patient management and to avoid the unnecessary use of less or ineffective drugs.

Acknowledgements

This work was partly supported by the Innovation and Technology Fund Midstream Research Programme for Universities (MRP/026/18) of the Innovation and Technology Commission, the Government of the Hong Kong Special Administrative Region. Any opinions, findings, conclusions or recommendations expressed in this material/event (or by members of the project team) do not reflect the views of the Government of the Hong Kong Special Administrative Region, the Innovation and Technology Commission or the Innovation and Technology Fund Research Projects Assessment Panel. We are grateful to Mrs Adrien Szekely of NCPF for providing the NCPF reference strains for free; Professor Maiken C. Arendrup and Dr Karin M. Jørgensen of SSI for providing the CNM-CL and CNM-CM reference strains for free; as well as the curators, especially Mr Travis W. Adkins, of NRRL for providing the NRRL reference strains for free. We also thank the Electron Microscope Unit of The University of Hong Kong which helped process the samples for scanning electron microscopy.

Disclosure statement









Patrick C. Y. Woo has provided scientific advisory/laboratory services for Gilead Sciences, Incorporated; International Health Management Associates, Incorporated; Merck & Corporation, Incorporated; Micología Molecular S.L. and Pfizer, Incorporated. The other authors report no conflicts of interest. The funding sources had no role in

study design, data collection, analysis, interpretation, or writing of the report. The authors alone are responsible for the content and the writing of the manuscript. Part of this study has been presented as an abstract for the 30th European Congress of Clinical Microbiology and Infectious Diseases.

Funding

This work was partly supported by the Innovation and Technology Fund Midstream Research Programme for Universities (grant number MRP/026/18) of the Innovation and Technology Commission, the Government of the Hong Kong Special Administrative Region. Any opinions, findings, conclusions or recommendations expressed in this material/event (or by members of the project team) do not reflect the views of the Government of the Hong Kong Special Administrative Region, the Innovation and Technology Commission or the Innovation and Technology Fund Research Projects Assessment Panel.

ORCID

Chi-Ching Tsang  <http://orcid.org/0000-0001-6705-2866>
 Ka-Fai Chan  <http://orcid.org/0000-0003-2290-3182>
 Walton Chan  <http://orcid.org/0000-0003-0909-8414>
 Jasper F. W. Chan  <http://orcid.org/0000-0001-6336-6657>
 Rex K. H. Au-Yeung  <http://orcid.org/0000-0002-3137-0886>
 Ken P. K. Lin  <http://orcid.org/0000-0002-0226-8874>
 Susanna K. P. Lau  <http://orcid.org/0000-0002-1383-7374>
 Patrick C. Y. Woo  <http://orcid.org/0000-0001-9401-1832>

References

- [1] Tulasne LR, Tulasne C. *Selecta Fungorum Carpologia* II. Paris: Imperiali Typographeo Excudebatur; 1863.
- [2] Réblová M, Jaklitsch WM, Réblová K, et al. Phylogenetic reconstruction of the Calosphaeriales and Togniniales using five genes and predicted RNA secondary structures of ITS, and *Flabellascus tenuirostris* gen. et sp. nov. *PLoS One*. 2015;10(12):e0144616.
- [3] Réblová M, Miller AN, Rossman AY, et al. Recommendations for competing sexual-aseually typified generic names in *Sordariomycetes* (except *Diaporthales*, *Hypocreales*, and *Magnaporthales*). *IMA Fungus*. 2016;7(1):131–153.
- [4] Schol-Schwarz MB. Revision of the genus *Phialophora* (Moniliales). *Persoonia*. 1970;6(1):59–94.
- [5] Barr ME. Notes on the Calosphaeriales. *Mycologia*. 1985;77(4):549–565.
- [6] Melin E, Nannfeldt JA. Researches into the blueing of ground wood-pulp. *Svenska Skogsvårdsför Tidskr*. 1934;32:397–430.
- [7] Moskowitz LB, Cleary TJ, McGinnis MR, et al. *Phialophora richardsiae* in a lesion appearing as a giant cell tumor of the tendon sheath. *Arch Pathol Lab Med*. 1983;107:374–376.
- [8] Singh SM, Agrawal A, Naidu J, et al. Cutaneous phaeohyphomycosis caused by *Phialophora richardsiae* and the effect of topical clotrimazole in its treatment. *Anton Leeuwenh*. 1992;61(1):51–55.
- [9] Levenstadt JS, Poutanen SM, Mohan S, et al. *Pleurostomophora richardsiae* – an insidious fungus presenting in a man 44 years after initial inoculation:

- a case report and review of the literature. *Can J Infect Dis Med Microbiol.* 2012;23(3):110–113.
- [10] Alam MS, Vaidehi D, Therese KL, et al. Rare *Pleurostomophora richardsiae* mass causing transient nasolacrimal duct obstruction. *Ophthal Plast Reconstr Surg.* 2017;33(6):e154–e156.
 - [11] Tee LY, Tan BH, Tan A-L, et al. Subcutaneous phaeohyphomycosis caused by *Pleurostomophora richardsiae* in a renal transplant recipient. *JAAD Case Rep.* 2020;6(1):66–68.
 - [12] Schwartz IS, Emmons CW. Subcutaneous cystic granuloma caused by a fungus of wood pulp (*Phialophora richardsiae*). *Am J Clin Pathol.* 1968;49(4):500–505.
 - [13] Corrado ML, Weitzman I, Stanek A, et al. Subcutaneous infection with *Phialophora richardsiae* and its susceptibility to 5-fluorocytosine, amphotericin B and miconazole. *Sabouraudia.* 1980;18(2):97–104.
 - [14] Reyes FA, Buchman MT. *Phialophora richardsiae* infection mimicking a soft tissue mass of a finger. *J Hand Surg Br.* 1986;11(2):274.
 - [15] Suppiah M, Chin CS, Keah KC. *Phialophora richardsiae* isolated from a cutaneous lesion. *Med J Malaysia.* 1987;42(4):306–308.
 - [16] Bonnefoy A, Luboinski J, Francoual S, et al. Phaeohyphomycosis due to *Phialophora richardsiae*. *Med Mal Infect.* 1988;18(4):235–238.
 - [17] Ikai K, Tomono H, Watanabe S. Phaeohyphomycosis caused by *Phialophora richardsiae*. *J Am Acad Dermatol.* 1988;19(3):478–481.
 - [18] Pitrak DL, Koneman EW, Estupinan RC, et al. *Phialophora richardsiae* infection in humans. *Rev Infect Dis.* 1988;10(6):1195–1203.
 - [19] Tam M, Freeman S. Phaeohyphomycosis due to *Phialophora richardsiae*. *Australas J Dermatol.* 1989;30(1):37–40.
 - [20] Guého E, Bonnefoy A, Luboinski J, et al. Subcutaneous granuloma caused by *Phialophora richardsiae*: case report and review of the literature *Phialophora richardsiae*. *Mycoses.* 1989;32(5):219–223.
 - [21] Jumaa PA, Lightowler C, Baker LRI, et al. Cutaneous infection caused by *Phialophora richardsiae* treated successfully by surgical excision in an immunocompromised patient. *J Infect.* 1995;30(3):261–262.
 - [22] Cornia PB, Raugi GJ, Miller RA. *Phialophora richardsiae* bursitis treated medically. *Am J Med.* 2003;115(1):77–79.
 - [23] Yehia M, Thomas M, Pilmore H, et al. Subcutaneous black fungus (phaeohyphomycosis) infection in renal transplant recipients: three cases. *Transplantation.* 2004;77(1):140–142.
 - [24] Sakayama K, Kidani T, Sugawara Y, et al. Mycetoma of foot: a rare case report and review of the literature. *Foot Ankle Int.* 2004;25(10):763–767.
 - [25] Son Y-M, Kang H-K, Na S-Y, et al. Chromoblastomycosis caused by *Phialophora richardsiae*. *Ann Dermatol.* 2010;22(3):362–366.
 - [26] Mhmod NA, Ahmed SA, Fahal AH, et al. *Pleurostomophora ochracea*, a novel agent of human eumycetoma with yellow grains. *J Clin Microbiol.* 2012;50(9):2987–2994.
 - [27] Amazan E, Desbois N, Fidelin G, et al. First case of phaeohyphomycosis due to *Pleurostoma ootheca* in a kidney transplant recipient in Martinique (French West Indies). *Med Sante Trop.* 2014;24(3):323–325.
 - [28] de Regt MJA, Murk J-L, Schneider-Hohendorf T, et al. Progressive multifocal leukoencephalopathy and black fungus in a patient with rheumatoid arthritis without severe lymphocytopenia. *JMM Case Rep.* 2016;3(4):e005053.
 - [29] Noguchi H, Hiruma M, Matsumoto T, et al. Subcutaneous cystic phaeohyphomycosis due to *Pleurostomophora richardsiae*. *J Dermatol.* 2017;44(4):e62–e63.
 - [30] Cuenca-Barrales C, De Salazar A, Chueca N, et al. Phaeohyphomycosis due to *Pleurostomophora richardsiae*: an uncommon cutaneous fungal infection. *J Eur Acad Dermatol Venereol.* 2018;32(10):e376–e377.
 - [31] Torstrick RF, Harrison K, Heckman JD, et al. Chronic bursitis caused by *Phialophora richardsiae*. A case report. *JBJS.* 1979;61(5):772–774.
 - [32] Yangco BG, TeStrake D, Okafor J. *Phialophora richardsiae* isolated from infected human bone: morphological, physiological and antifungal susceptibility studies. *Mycopathologia.* 1984;86(2):103–111.
 - [33] Uberti-Foppa C, Fumagalli L, Gianotti N, et al. First case of osteomyelitis due to *Phialophora richardsiae* in a patient with HIV infection. *AIDS.* 1995;9(8):975–976.
 - [34] Rossmann SN, Cernoch PL, Davis JR. Dematiaceous fungi are an increasing cause of human disease. *Clin Infect Dis.* 1996;22(1):73–80.
 - [35] Fox AR, Houser KH, Morris WR, et al. Dematiaceous fungal endophthalmitis: report of a case and review of the literature. *J Ophthalmic Inflamm Infect.* 2016;6(1):43.
 - [36] Listemann H. Die kulturelle untersuchung eines tranensteines mit isolierung des pilzes *Phialophora richardsiae*. *Ernst Rodenwaldt Arc.* 1975;2(2):45–52.
 - [37] Lieb DF, Smiddy WE, Miller D, et al. Case report: fungal endophthalmitis caused by *Phialophora richardsiae*. *Retina.* 2003;23(3):406–407.
 - [38] Polat SH, Kizilay F, Uyan A, et al. Urinary tract infection due to *Pleurostomophora richardsiae*. *Med Mycol.* 2018;56(Suppl. 2):S91.
 - [39] Juma A. *Phialophora richardsiae* endocarditis of aortic and mitral valves in a diabetic man with a porcine mitral valve. *J Infect.* 1993;27(2):173–175.
 - [40] Sribenjalux W, Chongtrakool P, Chayakulkeeree M. Disseminated phaeohyphomycosis with hepatic artery and portal vein thrombosis caused by *Pleurostomophora richardsiae* in a liver transplant recipient: a case report. *Transpl Infect Dis.* 2019;21(3):e13075.
 - [41] Ngan AHY. Atlas of fungi. Hong Kong: June Just Printing; 2016.
 - [42] Woo PCY, Ngan AHY, Tsang CCC, et al. Clinical spectrum of *Exophiala* infections and a novel *Exophiala* species, *Exophiala hongkongensis*. *J Clin Microbiol.* 2013;51(1):260–267.
 - [43] White T, Bruns T, Lee S, et al. Amplification and direct sequencing of fungal ribosomal RNA genes for phylogenetics. In: Innis M, Gelfand D, Shinsky J, editor. PCR protocols: a guide to methods and applications. San Diego: Academic Press; 1990. p. 315–322.
 - [44] O'Donnell K. *Fusarium* and its near relatives. In: Reynolds DR, Taylor JW, editor. The fungal holomorph: Mitotic, meiotic and pleomorphic speciation in fungal systematics. Wallingford: CAB International; 1993. p. 225–233.
 - [45] Cruse M, Telerant R, Gallagher T, et al. Cryptic species in *Stachybotrys chartarum*. *Mycologia.* 2002;94(5):814–822.
 - [46] Hall TA. Bioedit: a user-friendly biological sequence alignment editor and analysis program for Windows 95/98/NT. *Nucleic Acids Symp Ser.* 1999;41:95–98.

- [47] Edgar RC. MUSCLE: multiple sequence alignment with high accuracy and high throughput. *Nucleic Acids Res.* 2004;32(5):1792–1797.
- [48] Castresana J. Selection of conserved blocks from multiple alignments for their use in phylogenetic analysis. *Mol Biol Evol.* 2000;17(4):540–552.
- [49] Talavera G, Castresana J. Improvement of phylogenies after removing divergent and ambiguously aligned blocks from protein sequence alignments. *Syst Biol.* 2007;56(4):564–577.
- [50] Tamura K, Stecher G, Peterson D, et al. MEGA6: molecular evolutionary genetics analysis version 6.0. *Mol Biol Evol.* 2013;30(12):2725–2729.
- [51] Drummond AJ, Suchard MA, Xie D, et al. Bayesian phylogenetics with BEAUti and the BEAST 1.7. *Mol Biol Evol.* 2012;29(8):1969–1973.
- [52] Arendrup MC, Meletiadis J, Mouton JW. EUCAST definitive Document E.Def 9.3.1. Method for the determination of broth dilution minimum inhibitory concentrations of antifungal agents for conidia forming moulds 2017. Available from: http://www.eucast.org/fileadmin/src/media/PDFs/EUCAST_files/AFST/Files/EUCAST_E_Def_9_3_1_Mould_testing_definitive.pdf.
- [53] Tsang C-C, Tang JYM, Chan K-F, et al. Diversity of phenotypically non-dermatophyte, non-*Aspergillus* filamentous fungi causing nail infections: importance of accurate identification and antifungal susceptibility testing. *Emerg Microbes Infect.* 2019;8(1):531–541.
- [54] Tekpinar AD, Kalmer A. Utility of various molecular markers in fungal identification and phylogeny. *Nova Hedwigia.* 2019;109(1–2):187–224.
- [55] Vijaykrishna D, Mostert L, Jeewon R, et al. *Pleurostomophora*, an anamorph of *Pleurostoma* (*Calosphaerales*), a new anamorph genus morphologically similar to *Phialophora*. *Stud Mycol.* 2004;50:387–395.
- [56] Hironaga M, Nakano K, Yokoyama I, et al. *Phialophora repens*, an emerging agent of subcutaneous phaeohyphomycosis in humans. *J Clin Microbiol.* 1989;27(3):394–399.
- [57] Nakano K, Yokoyama I, Kitajima J, et al. A case of subcutaneous granuloma caused by *Phialophora repens*. *Rinsho Hifuka.* 1990;44(1):25–28.
- [58] Mostert L, Groenewald JZ, Summerbell RC, et al. Species of *Phaeoacremonium* associated with infections in humans and environmental reservoirs in infected woody plants. *J Clin Microbiol.* 2005;43(4):1752–1767.
- [59] European Committee on Antimicrobial Susceptibility Testing. Overview of antifungal ECOFFs and clinical breakpoints for yeasts, moulds and dermatophytes using the EUCAST E.Def 7.3, E.Def 9.3 and E.Def 11.0 procedures. Version 2, valid from 2020-09-24. 2020. Available from: <http://www.eucast.org/>.
- [60] Meyers WM, Dooley JR, Kwon-Chung KJ. Mycotic granuloma caused by *Phialophora repens*. *Am J Clin Pathol.* 1975;64(4):549–555.